

Review Article



OPEN ACCESS

Received: Apr 21, 2020

Accepted: May 19, 2020

Corresponding Author:

Marcos A. Sanchez-Gonzalez, MD, PhD

Sanchez-Gonzalez, MD, PhD. VP for Research & Academic Affairs, Division of Clinical & Translational Research, 7000 SW 62nd Ave, Suite 601, South Miami, FL 33143, USA.

Tel: +305-284-7608

Fax: +305-284-7545

E-mail: masanchez@larkinhospital.com

Copyright © 2020 by The Korean Society of Infectious Diseases, Korean Society for Antimicrobial Therapy, and The Korean Society for AIDS

This is an Open Access article distributed under the terms of the Creative Commons Attribution Non-Commercial License (<https://creativecommons.org/licenses/by-nc/4.0/>) which permits unrestricted non-commercial use, distribution, and reproduction in any medium, provided the original work is properly cited.

ORCID iDs

Marcos A. Sanchez-Gonzalez 
<https://orcid.org/0000-0002-7585-708X>
Dave Moskowitz 
<https://orcid.org/0000-0002-8891-7539>
Priya D. Issuree 
<https://orcid.org/0000-0002-8886-6436>
George Yatzkan 
<https://orcid.org/0000-0003-3911-9060>
Syed A. A. Rizvi 
<https://orcid.org/0000-0002-2385-5672>
Kenneth Day 
<https://orcid.org/0000-0001-8235-8302>

<https://icjournal.org>

A Pathophysiological Perspective on COVID-19's Lethal Complication: From Viremia to Hypersensitivity Pneumonitis-like Immune Dysregulation

Marcos A. Sanchez-Gonzalez ¹, Dave Moskowitz ², Priya D. Issuree ^{3,4}, George Yatzkan ⁵, Syed A. A. Rizvi ¹, and Kenneth Day ⁶

¹Division of Clinical & Translational Research, Larkin Health System, South Miami, Florida, USA

²GenoMed, Leesburg, Florida, USA

³Inflammation Program, Roy J. and Lucille A. Carver College of Medicine, University of Iowa, Iowa City, Iowa, USA

⁴Department of Internal Medicine, Roy J. and Lucille A. Carver College of Medicine, University of Iowa, Iowa City, Iowa, USA

⁵Intensive & Critical Care Unit, Larkin Health System, South Miami, FL, USA

⁶Zymo Research Corporation, Irvine, California, USA

ABSTRACT

Severe acute respiratory syndrome coronavirus 2 (SARS-CoV-2), the coronavirus responsible for our recent coronavirus disease 2019 pandemic, is driving a lung immunopathology that strongly resembles a severe form of hypersensitivity pneumonitis (HP). A review of recent Severe acute respiratory syndrome-related coronavirus (SARS-CoV) and SARS-CoV-2 medical reports, as well as described characteristics of HP, lead us to postulate a theory for SARS-CoV-2 severe disease. We propose that the novel SARS-CoV-2 can act as a trigger and substrate of an HP-like severe immune reaction especially in genetically vulnerable individuals in addition to those with immune senescence and dysregulation. Accordingly, the purpose of our letter is to shift the emphasis of concern surrounding immune activity from viral infection to an HP-like severe immune reaction. We review similarities in disease presentation between infection and allergy, relevant immunopathology, and outline phases of SARS-CoV-2 disease with perspectives on therapy and critical care. Altogether, the favored course is to begin treatments that address the disease at the earliest phase before immune dysregulation leading to uncontrolled pulmonary inflammation.

Keywords: Coronavirus disease 2019; Severe acute respiratory syndrome coronavirus 2; Hypersensitivity pneumonitis; Genetic Susceptibility; Immune Dysregulation

SYMPTOMS AND COMPUTED TOMOGRAPHY SCAN

A recent opinion report from Seoul, Korea suggested that the main lethal complication of the severe acute respiratory syndrome that results from severe acute respiratory syndrome coronavirus 2 (SARS-CoV-2) viral infection, also known as coronavirus Disease 2019

Conflict of Interest

No conflicts of interest.

Author Contributions

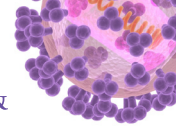
Conceptualization: MASG, KD. Writing - original draft: MASG, DM, PDI, GY, SAAR, KD. Writing - review & editing: MASG, DM, PDI, GY, SAAR, KD.

(COVID-19), is manifesting as a form of hypersensitivity pneumonitis (HP) [1]. Severe SARS-CoV-2 begins much like mild or moderate cases with symptoms such as dyspnea and cough, but may progress into a pneumonia-like disease with progression toward respiratory failure and pulmonary thrombosis [2]. These characteristics also resemble progression of HP with continued chronic exposure to antigen. Many of the common characteristics of COVID-19 such as chest tightness, cough, and dyspnea strongly overlap with features of HP [3]. A “two-hit” hypothesis has been suggested to promote HP, wherein preexisting genetic susceptibility or environmental factors (*i.e.*, the first hit) increases the risk for the development of HP after antigen exposure (the second hit). Over 300 substances (as the second hit) are known to act as triggers of HP such as avian-related antigens, birch wood with Gram-negative bacteria, molds, cheese, fungus, hay, and chemicals [4-7]. Viral antigens can induce HP as influenza virus and coronavirus antigens are often found in bronchoalveolar lavage (BAL) cells and lung tissue of patients with HP that indicate a critical role of viruses as a trigger driving manifestation of the disease [8-10]. We propose a theory that the novel COVID-19 can act as a trigger and substrate of an HP-like severe immune reaction especially in genetically vulnerable individuals and those with immune senescence and dysregulation. Chronic HP is typically managed by isolating the antigen that incites disease, and shortened survival was associated with inability to identify antigen [11]. If SARS-CoV-2 infection is viewed from the perspective that it is increased exposure to inciting antigen as an HP-like response leading to a severe immune reaction, this also changes perspectives on treatments.

HP is subdivided into acute, subacute, and chronic forms based on pathophysiology [12]. Acute HP is characterized by cough, chest tightness, dyspnea with neutrophilic infiltration, pulmonary fibrin formation, and thoracic computed tomography (CT) scan ground glass opacity (GGO) with reticulonodular pattern [13]. Acute HP symptoms such as fever and cough often resemble influenza, and continued exposure to an allergen can drive progression toward chronic disease [14]. Subacute HP displays similar symptoms as acute forms, except that the lung pathology escalates toward interstitial infiltrates with bronchiolitis and GGO exhibiting centriobular nodules [13, 15]. Chronic HP shows escalated symptoms with increased lymphocyte, mast cell, and eosinophil infiltration into the lungs with neutrophil activity. CT features in severe SARS-CoV-2 cases were described to have GGO associated with non-infectious lung conditions described as subpleural air-space disease with GGO features being detected even in the earliest mild asymptomatic patients [16]. However, while GGO and symptoms presented together show similarity between severe SARS-CoV-2 and HP-like illness, these features alone cannot conclusively determine that they are the same disease as very often GGO cannot distinguish between infectious and non-infectious disease conditions [17]. In fact, chronic HP exhibit GGO that overlap with interstitial pneumonia, and therefore is commonly misdiagnosed as such [13, 18].

IMMUNOPATHOLOGY

HP is a combination of type III and IV hypersensitivity directed toward allergen that drives the development of immune complexes with T cell activity that shifts toward a Th2 response [12]. With an increased presence of immune complexes, complement cascade activity is well established as a characteristic of HP [19, 20]. Interestingly, these features resemble the progress of severe SARS-CoV-2 disease [21]. Both chronic HP and SARS-CoV-2 can progress toward hyperinflammation in the lungs that may promote coagulation and thrombosis [2]. As a component of a Th2 response, eosinophil activity may be a “double-edged sword” also



as a shared feature between respiratory virus infection and allergy. Eosinophils destroy ssRNA genomes of respiratory tract viruses through their ribonucleases via the TLR7 receptor [22]. TLR4 and TLR7 receptors balance Th1 and Th2 immunity [23]. SARS-CoV (SARS-CoV fullname) ssRNA signaling through TLR7 stimulated IL-6 and TNF expression almost 2-fold greater than other viruses [24]. IL-6 strongly predicts severe SARS-CoV-2 cases and is a major target for blocking downstream macrophage activation syndrome [25]. IL-4 and IL-13 signaling among mast cell activity recruits eosinophils from the bone marrow into the lung through IL-5, a cytokine required for clearance of virus and detected in severe SARS-CoV-2 patients [26-28]. Mast cells were 1000-fold higher in BAL of HP patients, and analysis of excessive amounts of histamine in the fluid suggested that the lavage procedure may promote mast cell degranulation [29]. In this vein, eosinopenia in severe SARS-CoV-2 cases and may suggest migration to the lungs [30]. Autopsy has confirmed eosinophils in the lung, and restoration of eosinophil counts in the blood are predictive of SARS-CoV-2 resolution by also testing negative via reverse transcription polymerase chain reaction (RT-PCR) signifying viral clearance [31, 32]. Blood eosinophil levels with increased neutrophil to lymphocyte ratio were linked to severe patients that remained in the intensive care unit (ICU) while remaining RT-PCR positive [33, 34]). Elevated NK and NKT cells were positively correlated with eosinophils among interstitial lung diseases that include HP [35].

Besides HP, shared immune activity between infection and other allergic airway inflammation is well established. Asthma induction in children is strongly linked to hypersensitivity response to Respiratory Syncytial Virus (RSV), while in older individuals, asthma may be connected to rhinovirus [36, 37]. Virulent pneumonia virus of mice (PVM) is not well cleared by eosinophils and may actually better represent acute respiratory distress syndrome (ARDS) caused by RSV infection in humans [38]. PVM-infected mice show rapid replication with eosinophilic response, granulocyte recruitment, edema, inflammation, respiratory failure, and death [39]. *TMPRSS2* and *ACE2* are the two main host genes required for SARS-CoV-2 entry into cells, and *ACE2* is the receptor for the SARS-CoV-2 spike protein (PMID: 32142651). Recent work among 695 asthmatic and healthy child cases showed that *TMPRSS2* expression was upregulated by the Th2 response, while *ACE2* was downregulated, and suggested that low-level airway inflammation may be protective against SARS-CoV-2 infection [40]. Asthma comorbidity is far less frequent among other comorbidities in SARS-CoV-2 severe cases [41]. It is possible that asthmatics may self-treat with inhaled prescription corticosteroids upon symptoms accompanying SARS-CoV-2 infection. Altogether, poor outcomes during hypersensitivity reactions leading to ARDS may coalesce with mechanisms to clear viral infection.

Poor eosinophilic anti-viral activity among more virulent respiratory infections may be a part of disease initiation [42]. For instance, Vaccination alone of many respiratory viruses induced pulmonary eosinophilia and enhanced lung disease with hypersensitivity upon challenge of infection [43]. Macaques vaccinated with human metapneumovirus and challenged also developed eosinophilic pathology and hypersensitivity [44]. As expected, candidate SARS-CoV vaccines tested in animals also exhibited the same Th2 lung immunopathology [45]. Similar immunopathology in mice was replicated, and also showed that the nucleocapsid alone could trigger the hypersensitivity response with very poor outcomes for aged mice [46]. Collectively, this raised safety concerns for the double inactivated SARS-CoV vaccine in the elderly [46], and also suggested that eosinophils may contribute to early immune dysregulation independent of their anti-viral activity.

POOR OUTCOMES AND GENETIC SUSCEPTIBILITY

Similar to chronic disease manifestations in HP, poor outcomes of SARS-CoV-2 severity include fibrosis and lung injury [47]. Expression of *TMPRSS2* was also associated with other gene expression enriched in mucus goblet cell markers within the lung and eosinophil levels were suggested as a proxy measurement for Th2 airway inflammation and severity of outcomes [40]. While the environmental triggers associated with HP have been extensively studied, the contribution of genetics in disease progression is still not well understood. A variant rs35705950 located near *MUC5B* could contribute to risk for severe and moderate chronic HP using metrics of fibrosis measured by CT, and comparisons to healthy controls yielded odds ratios of 2.27 to 3 [48, 49]. Poor outcomes in chronic HP were more strongly associated with telomeropathy. Variants in telomere-related genes were associated with shorter peripheral blood telomere lengths in a discovery and replication cohort with age, sex and ancestry adjustment containing a hazard ratio of 3.73, and there were significant differences in survivorship according to telomere lengths stratified by the 10th percentile for age [50, 51]. Telomere length is also associated with other interstitial lung diseases with pulmonary fibrosis in peripheral blood, but not within lung tissue [52]. Since telomeres typically shorten with age, but different rates of shortening may allow for measuring chronological versus biological aging and SARS-CoV-2 severe cases have a strong connection to aging, it would be interesting to measure association with telomere length, especially in younger patients with severe disease.

Mouse models of HP recently identified a QTL on chromosome 18 implicating the candidate gene *Cdh2* with corroborating evidence of cadherin 2 upregulation in the lungs of chronic HP-induced mice that may be indicative of epithelial to mesenchymal transition responsible for progression toward fibrosis [53]. fibrotic disease is also typically associated with progression toward hypercoagulation [54], and this is a feature of SARS-CoV and SARS-CoV-2 severe disease as well. Memory Th2 cells may promote airway inflammation and fibrosis through the reprogramming of eosinophils to upregulate the production of osteopontin, or *SPP1* [55]. A recent single-cell RNA-seq study of mild and severe SARS-CoV-2 BAL samples showed *SPP1* was elevated as distinguishing gene expression marker in severe versus mild disease [56]. Currently, there are no genome-wide studies available for host genotype on the severity of SARS-CoV-2, but analysis of these discussed loci in the context of severe HP may be a starting point. However, the allele rs12252 located near the *IFITM3* gene was associated with severe versus mild SARS-CoV-2 cases of Asian ancestry with odds ratio of 11.67 and 6.37 with adjustment for age [57]. *IFITM3*, which is expressed in CD4⁺ T cells, and was downregulated during activation confers protection against a variety of viruses that include RSV and SARS-CoV as an absence of these genes in mice reduced eosinophilia and was protective against allergy and asthma [58, 59].

Based on the overlap in cell and molecular immunopathology, it seems reasonable to suggest that the disease manifesting itself as COVID-19 may immune dysregulation driven by an HP-like severe immune response triggered by the excessive viral load as secondary to the infection [1]. Understanding the role of eosinophils could be the key to understanding the disease as a hypersensitivity-like response [60]. More studies require autopsy reports, collections of BAL, and animal models to better characterize the similarities between HP-like disease and SARS-CoV-2 severity. Our observations should be an important consideration for the development of vaccines for SARS-CoV-2 [61], and also provides an opportunity to treat patients early. For HP itself, often the inability to determine the offending antigen is strongly

associated with poor survivorship [11]. With the perspective that SARS-CoV-2 virus may drive HP-like immune dysregulation, it might be possible to prevent systemic severe hyper-cytokinemic inflammatory state or cytokine storm that results in macrophage activation syndrome [62].

PHASES FROM VIREMIA TO HYPERSENSITIVITY PNEUMONITIS-LIKE SEVERE IMMUNE RESPONSE

1. Phase I

Based on the clinical features, vaccine studies of SARS-CoV, and similarities to HP, an aggressive blockage of allergic and hypersensitivity responses could be of clinical relevance in the treatment of COVID-19. One potential therapeutic approach could be to block Mast cell and EOS responses early in the course of the COVID-19 infection (days 2 - 5) defined here as *Phase I* (EOS and NEU/LYM baseline). As the viral load increases so do the allergen/antigens creating a similar environment to the pathophysiology of HP. Interestingly, chest X-ray findings in COVID-19 patients are consistent with those of HP including the most important complication, lung fibrosis [63, 64]. Mast cell stabilizers (*i.e.* β 2-adrenergic agonists, Cromoglicic acid, Ketotifen) and eosinophil blocking agents (*i.e.* Omalizumab, Mepolizumab) could key players in delaying or preventing the lethality of the SARS-CoV-2-induced hypersensitivity-like response.

2. Phase II

As COVID-19 progresses, 5 - 9 days into disease, EOS "migrate to the lungs" and hence the marked decrease in the blood *Phase II* (Blood Count Finding; \downarrow EOS and \uparrow NEU/LYM). The Phase II response is consistent with histopathology seen in animals given the SARS-CoV vaccines displaying Th2-type immunopathology with prominent EOS infiltration [45]. Interestingly, allergic patients and asthmatics typically use medications that control these adverse responses in the first place which may lead to no severe co-morbidity cases of asthma patients as suggested by current reports [41, 63].

3. Phase III

Once the SARS-CoV-2-induced HP-like severe immune response is fully active, respiratory distress syndrome, the lungs get affected by uncontrolled inflammation, fluid accumulation, lymphocyte-dominant interstitial inflammatory cell infiltration, progressive fibrosis will begin to severely compromise the gas exchange, acute *Phase III* (\downarrow LYM) [65]. As pneumocyte dysfunction installs, owing to both viral infectivity and increased immune hypersensitive response, there is a decrease in the production of surfactant inducing impaired gas exchange [66]. These findings are consistent with reports describing CT impressions and pulmonary fibrosis in COVID-19 survivors and [67, 68]. Increased fluid in the lungs and less oxygen in the circulation leads to increased myocardial right ventricular work and oxygen consumption that become an advanced critical complication for those with cardiac conditions. It is plausible that the use of anticoagulant administration in Phase III may ameliorate the diffusion problem and improve oxygen saturation as a severe complication is the development of pulmonary thromboembolism that have been reported in HP [69]. Noteworthy, many of the aforementioned findings are consistent with those of severe interstitial pulmonary disease or late chronic HP in which neither non-invasive ventilation nor invasive mechanical ventilation seems to change the poor outcomes associated with advanced stages [70]. Patients diagnoses with COVID-19 that are under ventilatory support have been reported to have the highest mortality.

Table 1. Description and progression and management of the COVID-19 induced HP

COVID-19 phase from symptom onset (day)	Key clinical features	Recommended therapeutic approach	Critical care key points
Phase I (day 2 - 5)	<ul style="list-style-type: none"> · ↑Viral load and allergen/antigens creating a similar environment to the pathophysiology of HP · Check EOS and NEU/LYM baseline counts 	<ul style="list-style-type: none"> · Early antiviral treatment lopinavir/ritonavir · Aggressive blockage of allergic and hypersensitivity reaction · Antihistamines · Mast cell stabilizers (i.e. β2-adrenergic agonists, Cromoglicic acid, Ketotifen) and eosinophil blocking agents (i.e. Omalizumab, Mepolizumab) 	<p>Main Goal I: To block the cytokine storm</p> <ul style="list-style-type: none"> · Steroids, immunosuppressors, high flow nasal cannula, with uttermost caution regarding aerosolized particles · Immunosuppressant, high dose steroids is key, 1 mg/kg daily methylprednisolone, avoid intubation, decrease viral load with anti-viral meds
Phase II (day 5 - 8)	<ul style="list-style-type: none"> · Th2-type immunopathology with prominent EOS infiltration lungs · ↓EOS [$<0.2\%$] and ↑NEU/LYM [>5] · Onset of decrease Oxygen saturation · HP 	<ul style="list-style-type: none"> · Methylprednisolone at a dose of 80 mg per day, either as a single daily dose, or as 40 mg bd · Interleukin blockers · Theophylline 	<p>Main Goal II: To avoid intubation</p> <ul style="list-style-type: none"> · High dose steroids (0.15 mg/kg dexamethasone q6h or 250 - 500 mg daily methylprednisolone is a must, plus interleukin blockers
Phase III (day 8 - 10>)	<ul style="list-style-type: none"> · Uncontrolled inflammation, fluid accumulation, lymphocyte-dominant interstitial inflammatory cell infiltration, progressive fibrosis will begin to severely compromise the gas exchange (ARDS) · ↓LYM · Cytokine storm 	<ul style="list-style-type: none"> · Surfactant administration · Mucolytics, even bronchoscopy 	<p>Main Goal III: To clear fluid from lungs</p> <ul style="list-style-type: none"> · Focus on aggressive pulmonary toiletry, frequent suction, ventilatory demands are different from ARDS, low peep and low oxygen supply are key

COVID-19, coronavirus disease 2019; HP, hypersensitivity pneumonitis; EOS, eosinophils; NEU, neutrophils; LYM, lymphocytes, ARDS, acute respiratory distress syndrome.

In summary, COVID-19 complication and progression may take three phases that mimic HP as the virus is simultaneously the substrate and trigger of the altered immune response and ARDS. Prospective therapeutic strategies aimed at identifying those individuals that are genetically susceptible as well as hypersensitive individuals might decrease the main complications of the disease. Furthermore, the earlier the disease is recognized as a hypersensitive-like response, the quicker it can be treated at earlier phases to prevent progression into severe disease (**Table 1**). Research studies designed to understand the underlying mechanisms accountable for the HP-like severe immune response in severely ill COVID-19 patients are warranted.

REFERENCES

1. Song YG, Shin HS. COVID-19, a clinical syndrome manifesting as hypersensitivity pneumonitis. *Infect Chemother* 2020;52:110-2.
[PUBMED](#) | [CROSSREF](#)
2. Lax SF, Skok K, Zechner P, Kessler HH, Kaufmann N, Koelblinger C, Vander K, Bargfrieder U, Trauner M. Pulmonary arterial thrombosis in COVID-19 with fatal outcome: results from a prospective, single-center, clinicopathologic case series. *Ann Intern Med* 2020. [Epub ahead of print].
[PUBMED](#) | [CROSSREF](#)
3. Wu F, Zhao S, Yu B, Chen YM, Wang W, Song ZG, Hu Y, Tao ZW, Tian JH, Pei YY, Yuan ML, Zhang YL, Dai FH, Liu Y, Wang QM, Zheng JJ, Xu L, Holmes EC, Zhang YZ. A new coronavirus associated with human respiratory disease in China. *Nature* 2020;579:265-9.
[PUBMED](#) | [CROSSREF](#)
4. Inoue Y, Ishizuka M, Furusawa H, Honda T, Kawahara T, Tateishi T, Miyazaki Y. Acute inflammatory and immunologic responses against antigen in chronic bird-related hypersensitivity pneumonitis. *Allergol Int* 2019;68:321-8.
[PUBMED](#) | [CROSSREF](#)

5. Mackiewicz B, Dutkiewicz J, Siwiec J, Kucharczyk T, Siek E, Wójcik-Fatla A, Cholewa G, Cholewa A, Paściak M, Pawlik K, Szponar B, Milanowski J. Acute hypersensitivity pneumonitis in woodworkers caused by inhalation of birch dust contaminated with *Pantoea agglomerans* and *Microbacterium barkeri*. *Ann Agric Environ Med* 2019;26:644-55.
[PUBMED](#) | [CROSSREF](#)
6. Metzger F, Haccuria A, Reboux G, Nolard N, Dalphin JC, De Vuyst P. Hypersensitivity pneumonitis due to molds in a saxophone player. *Chest* 2010;138:724-6.
[PUBMED](#) | [CROSSREF](#)
7. Sahin H, Kaproth-Joslin K, Hobbs SK. Hypersensitivity pneumonitis. *Semin Roentgenol* 2019;54:37-43.
[PUBMED](#) | [CROSSREF](#)
8. Cormier Y, Israël-Assayag E. The role of viruses in the pathogenesis of hypersensitivity pneumonitis. *Curr Opin Pulm Med* 2000;6:420-3.
[PUBMED](#) | [CROSSREF](#)
9. Dakhama A, Hegele RG, Laflamme G, Israël-Assayag E, Cormier Y. Common respiratory viruses in lower airways of patients with acute hypersensitivity pneumonitis. *Am J Respir Crit Care Med* 1999;159:1316-22.
[PUBMED](#) | [CROSSREF](#)
10. Gudmundsson G, Monick MM, Hunninghake GW. Viral infection modulates expression of hypersensitivity pneumonitis. *J Immunol* 1999;162:7397-401.
[PUBMED](#)
11. Fernández Pérez ER, Swigris JJ, Forssén AV, Tourin O, Solomon JJ, Huie TJ, Olson AL, Brown KK. Identifying an inciting antigen is associated with improved survival in patients with chronic hypersensitivity pneumonitis. *Chest* 2013;144:1644-51.
[PUBMED](#) | [CROSSREF](#)
12. Watts MM, Grammer LC. Hypersensitivity pneumonitis. *Allergy Asthma Proc* 2019;40:425-8.
[PUBMED](#) | [CROSSREF](#)
13. D'souza RS, Donato A. Hypersensitivity pneumonitis: an overlooked cause of cough and dyspnea. *J Community Hosp Intern Med Perspect* 2017;7:95-9.
[PUBMED](#) | [CROSSREF](#)
14. Chandra D, Cherian SV. Hypersensitivity Pneumonitis. StatPearls. Treasure Island (FL): StatPearls Publishing StatPearls Publishing LLC.; 2020.
15. Magee AL, Montner SM, Husain A, Adegunsoye A, Vij R, Chung JH. Imaging of hypersensitivity pneumonitis. *Radiol Clin North Am* 2016;54:1033-46.
[PUBMED](#) | [CROSSREF](#)
16. Shi H, Han X, Jiang N, Cao Y, Alwalid O, Gu J, Fan Y, Zheng C. Radiological findings from 81 patients with COVID-19 pneumonia in Wuhan, China: a descriptive study. *Lancet Infect Dis* 2020;20:425-34.
[PUBMED](#) | [CROSSREF](#)
17. Miller WT Jr, Shah RM. Isolated diffuse ground-glass opacity in thoracic CT: causes and clinical presentations. *AJR Am J Roentgenol* 2005;184:613-22.
[PUBMED](#) | [CROSSREF](#)
18. Silva CIS, Churg A, Müller NL. Hypersensitivity pneumonitis: spectrum of high-resolution CT and pathologic findings. *AJR Am J Roentgenol* 2007;188:334-44.
[PUBMED](#) | [CROSSREF](#)
19. Yoshizawa Y, Nomura A, Ohdama S, Tanaka M, Morinari H, Hasegawa S. The significance of complement activation in the pathogenesis of hypersensitivity pneumonitis: sequential changes of complement components and chemotactic activities in bronchoalveolar lavage fluids. *Int Arch Allergy Appl Immunol* 1988;87:417-23.
[PUBMED](#) | [CROSSREF](#)
20. Regal JF. Role of the complement system in pulmonary disorders. *Immunopharmacology* 1997;38:17-25.
[PUBMED](#) | [CROSSREF](#)
21. Gralinski LE, Sheahan TP, Morrison TE, Menachery VD, Jensen K, Leist SR, Whitmore A, Heise MT, Baric RS. Complement activation contributes to severe acute respiratory syndrome coronavirus pathogenesis. *MBio* 2018;9:e01753-18.
[PUBMED](#) | [CROSSREF](#)
22. Domachowske JB, Dyer KD, Bonville CA, Rosenberg HF. Recombinant human eosinophil-derived neurotoxin/RNase 2 functions as an effective antiviral agent against respiratory syncytial virus. *J Infect Dis* 1998;177:1458-64.
[PUBMED](#) | [CROSSREF](#)
23. Goff PH, Hayashi T, He W, Yao S, Cottam HB, Tan GS, Crain B, Krammer F, Messer K, Pu M, Carson DA, Palese P, Corr M. Synthetic toll-like receptor 4 (TLR4) and TLR7 ligands work additively via MyD88 to induce protective antiviral immunity in mice. *J Virol* 2017;91:e01050-17.
[PUBMED](#) | [CROSSREF](#)

24. Li Y, Chen M, Cao H, Zhu Y, Zheng J, Zhou H. Extraordinary GU-rich single-strand RNA identified from SARS coronavirus contributes an excessive innate immune response. *Microbes Infect* 2013;15:88-95.
[PUBMED](#) | [CROSSREF](#)
25. McGonagle D, Sharif K, O'Regan A, Bridgewood C. The role of cytokines including interleukin-6 in COVID-19 induced pneumonia and macrophage activation syndrome-like disease. *Autoimmun Rev* 2020;19:102537.
[PUBMED](#) | [CROSSREF](#)
26. Phipps S, Lam CE, Mahalingam S, Newhouse M, Ramirez R, Rosenberg HF, Foster PS, Matthaei KI. Eosinophils contribute to innate antiviral immunity and promote clearance of respiratory syncytial virus. *Blood* 2007;110:1578-86.
[PUBMED](#) | [CROSSREF](#)
27. Li CK, Wu H, Yan H, Ma S, Wang L, Zhang M, Tang X, Temperton NJ, Weiss RA, Brenchley JM, Douek DC, Mongkolsapaya J, Tran BH, Lin CS, Sreaton GR, Hou JL, McMichael AJ, Xu XN. T cell responses to whole SARS coronavirus in humans. *J Immunol* 2008;181:5490-500.
[PUBMED](#) | [CROSSREF](#)
28. Bouadma L, Wiedemann A, Patrier J, Surenaud M, Wicky P-H, Foucat E, Diehl JL, Hejblum BP, Sinnah F, de Montmollin E, Lacabaratz C, Thiebaut R, Timsit JE, Levy Y. Immune alterations during SARS-CoV-2-related acute respiratory distress syndrome. *medRxiv* 2020:2020.05.01.20087239.
29. Soler P, Nioche S, Valeyre D, Basset F, Benveniste J, Burtin C, Battesti JP, Georges R, Hance AJ. Role of mast cells in the pathogenesis of hypersensitivity pneumonitis. *Thorax* 1987;42:565-72.
[PUBMED](#) | [CROSSREF](#)
30. Cheng Y, Zhou Y, Zhu M, Zha L, Lu Z, Ding Z, Yang J, Yang G. Eosinopenia phenotype in patients with coronavirus disease 2019: a multi-center retrospective study from Anhui, China. *medRxiv* 2020:2020.04.22.20071050.
31. Yao XH, Li TY, He ZC, Ping YF, Liu HW, Yu SC, Mou HM, Wang LH, Zhang HR, Fu WJ, Luo T, Liu F, Guo QN, Chen C, Xiao HL, Guo HT, Lin S, Xiang DF, Shi Y, Pan GQ, Li QR, Huang X, Cui Y, Liu XZ, Tang W, Pan PF, Huang XQ, Ding YQ, Bian XW. A pathological report of three COVID-19 cases by minimally invasive autopsies. *Zhonghua Bing Li Xue Za Zhi* 2020;49:411-7.
[PUBMED](#)
32. Liu F, Xu A, Zhang Y, Xuan W, Yan T, Pan K, Yu W, Zhang J. Patients of COVID-19 may benefit from sustained lopinavir-combined regimen and the increase of eosinophil may predict the outcome of COVID-19 progression. *Int J Infect Dis* 2020;95:183-91.
[PUBMED](#) | [CROSSREF](#)
33. Qin C, Zhou L, Hu Z, Zhang S, Yang S, Tao Y, Xie C, Ma K, Shang K, Wang W, Tian DS. Dysregulation of immune response in patients with COVID-19 in Wuhan, China. *Clin Infect Dis* 2020;ciaa248. [Epub ahead of print].
[PUBMED](#) | [CROSSREF](#)
34. Cao X. COVID-19: immunopathology and its implications for therapy. *Nat Rev Immunol* 2020;20:269-70.
[PUBMED](#) | [CROSSREF](#)
35. Papakosta D, Manika K, Kyriazis G, Kontakiotis T, Gioulekas D, Polyzoni T, Bouros D, Patakas D. Bronchoalveolar lavage fluid eosinophils are correlated to natural killer cells in eosinophilic pneumonias. *Respiration* 2009;78:177-84.
[PUBMED](#) | [CROSSREF](#)
36. Jartti T, Gern JE. Role of viral infections in the development and exacerbation of asthma in children. *J Allergy Clin Immunol* 2017;140:895-906.
[PUBMED](#) | [CROSSREF](#)
37. Wark PAB, Ramsahai JM, Pathinayake P, Malik B, Bartlett NW. Respiratory viruses and asthma. *Semin Respir Crit Care Med* 2018;39:45-55.
[PUBMED](#) | [CROSSREF](#)
38. Dyer KD, Garcia-Crespo KE, Glineur S, Domachowski JB, Rosenberg HF. The pneumonia virus of mice (PVM) model of acute respiratory infection. *Viruses* 2012;4:3494-510.
[PUBMED](#) | [CROSSREF](#)
39. Bonville CA, Bennett NJ, Koehnlein M, Haines DM, Ellis JA, DelVecchio AM, Rosenberg HF, Domachowski JB. Respiratory dysfunction and proinflammatory chemokines in the pneumonia virus of mice (PVM) model of viral bronchiolitis. *Virology* 2006;349:87-95.
[PUBMED](#) | [CROSSREF](#)
40. Sajuthi SP, DeFord P, Jackson ND, Montgomery MT, Everman JL, Rios CL, Pruesse E, Nolin JD, Plender EG, Wechsler ME, Mak AC, Eng C, Salazar S, Medina V, Wohlford EM, Huntsman S, Nickerson DA, Germer S, Zody MC, Abecasis G, Kang HM, Rice KM, Kumar R, Oh S, Rodriguez-Santana J, Burchard EG, Seibold MA. Type 2 and interferon inflammation strongly regulate SARS-CoV-2 related gene expression in the airway epithelium. *bioRxiv* 2020:2020.04.09.034454. [Epub ahead of print].
[PUBMED](#)

41. Zhang JJ, Dong X, Cao YY, Yuan YD, Yang YB, Yan YQ, Akdis CA, Gao YD. Clinical characteristics of 140 patients infected with SARS-CoV-2 in Wuhan, China. *Allergy* 2020. [Epub ahead of print].
[PUBMED](#) | [CROSSREF](#)
42. Eng SS, DeFelice ML. The Role and immunobiology of eosinophils in the respiratory system: a comprehensive review. *Clin Rev Allergy Immunol* 2016;50:140-58.
[PUBMED](#) | [CROSSREF](#)
43. Li K, Li Z, Wohlford-Lenane C, Meyerholz DK, Channappanavar R, An D, Perlman S, McCray PB Jr, He B. Single-dose, intranasal immunization with recombinant parainfluenza virus 5 expressing middle east respiratory syndrome coronavirus (MERS-CoV) spike protein protects mice from fatal MERS-CoV infection. *MBio* 2020;11:e00554-20.
[PUBMED](#) | [CROSSREF](#)
44. de Swart RL, van den Hoogen BG, Kuiken T, Herfst S, van Amerongen G, Yüksel S, Sprong L, Osterhaus ADME. Immunization of macaques with formalin-inactivated human metapneumovirus induces hypersensitivity to hMPV infection. *Vaccine* 2007;25:8518-28.
[PUBMED](#) | [CROSSREF](#)
45. Tseng CT, Sbrana E, Iwata-Yoshikawa N, Newman PC, Garron T, Atmar RL, Peters CJ, Couch RB. Immunization with SARS coronavirus vaccines leads to pulmonary immunopathology on challenge with the SARS virus. *PLoS One* 2012;7:e35421.
[PUBMED](#) | [CROSSREF](#)
46. Bolles M, Deming D, Long K, Agnihothram S, Whitmore A, Ferris M, Funkhouser W, Gralinski L, Totura A, Heise M, Baric RS. A double-inactivated severe acute respiratory syndrome coronavirus vaccine provides incomplete protection in mice and induces increased eosinophilic proinflammatory pulmonary response upon challenge. *J Virol* 2011;85:12201-15.
[PUBMED](#) | [CROSSREF](#)
47. Gralinski LE, Bankhead A 3rd, Jeng S, Menachery VD, Proll S, Belisle SE, Matzke M, Webb-Robertson BJM, Luna ML, Shukla AK, Ferris MT, Bolles M, Chang J, Aicher L, Waters KM, Smith RD, Metz TO, Law GL, Katze MG, McWeeney S, Baric RS. Mechanisms of severe acute respiratory syndrome coronavirus-induced acute lung injury. *MBio* 2013;4:e00271-13.
[PUBMED](#) | [CROSSREF](#)
48. López-Mejías R, Remuzgo-Martínez S, Genre F, Pulito-Cueto V, Rozas SMF, Llorca J, Fernández DI, Cuesta VMM, Ortego-Centeno N, Gómez NP, Mera-Varela A, Martínez-Barrio J, López-Longo FJ, Mijares V, Lera-Gómez L, Usetti MP, Laporta R, Pérez V, Gafas AP, González MAA, Calvo-Alén J, Romero-Bueno F, Sanchez-Pernaute O, Nuno L, Bonilla G, Balsa A, Hernández-González F, Grafia I, Prieto-González S, Narvaez J, Trallero-Araguas E, Selva-O'Callaghan A, Gualillo O, Castañeda S, Cavagna L, Cifrian JM, González-Gay MA. Influence of MUC5B gene on antisynthetase syndrome. *Sci Rep* 2020;10:1415.
[PUBMED](#) | [CROSSREF](#)
49. Ley B, Newton CA, Arnould I, Elicker BM, Henry TS, Vittinghoff E, Golden JA, Jones KD, Batra K, Torrealba J, Garcia CK, Wolters PJ. The MUC5B promoter polymorphism and telomere length in patients with chronic hypersensitivity pneumonitis: an observational cohort-control study. *Lancet Respir Med* 2017;5:639-47.
[PUBMED](#) | [CROSSREF](#)
50. Ley B, Torgerson DG, Oldham JM, Adegunsoye A, Liu S, Li J, Elicker BM, Henry TS, Golden JA, Jones KD, Dressen A, Yaspan BL, Arron JR, Noth I, Hoffmann TJ, Wolters PJ. Rare protein-altering telomere-related gene variants in patients with chronic hypersensitivity pneumonitis. *Am J Respir Crit Care Med* 2019;200:1154-63.
[PUBMED](#) | [CROSSREF](#)
51. Bouros D, Tzouveleki A. Telomeropathy in chronic hypersensitivity pneumonitis. *Am J Respir Crit Care Med* 2019;200:1086-7.
[PUBMED](#) | [CROSSREF](#)
52. Courtwright AM, El-Chemaly S. Telomeres in interstitial lung disease: The short and the long of it. *Ann Am Thorac Soc* 2019;16:175-81.
[PUBMED](#) | [CROSSREF](#)
53. Wang J, Yoon TW, Read R, Yi AK, Williams RW, Fitzpatrick EA. Genetic variability of T cell responses in hypersensitivity pneumonitis identified using the BXD genetic reference panel. *Am J Physiol Lung Cell Mol Physiol* 2020;318:L631-43.
[PUBMED](#) | [CROSSREF](#)
54. Sprunger DB, Olson AL, Huie TJ, Fernandez-Perez ER, Fischer A, Solomon JJ, Brown KK, Swigris JJ. Pulmonary fibrosis is associated with an elevated risk of thromboembolic disease. *Eur Respir J* 2012;39:125-32.
[PUBMED](#) | [CROSSREF](#)
55. Morimoto Y, Hirahara K, Kiuchi M, Wada T, Ichikawa T, Kanno T, Okano M, Kokubo K, Onodera A, Sakurai D, Okamoto Y, Nakayama T. Amphiregulin-producing pathogenic memory T helper 2 cells instruct eosinophils to secrete osteopontin and facilitate airway fibrosis. *Immunity* 2018;49:134-150.e6.
[PUBMED](#) | [CROSSREF](#)

56. Liao M, Liu Y, Yuan J, Wen Y, Xu G, Zhao J, Chen L, Li J, Wang X, Wang F, Liu L, Zhang S, Zhang Z. The landscape of lung bronchoalveolar immune cells in COVID-19 revealed by single-cell RNA sequencing. medRxiv 2020:2020.02.23.20026690.
57. Zhang Y, Qin L, Zhao Y, Zhang P, Xu B, Li K, Liang L, Zhang C, Dai Y, Feng Y, Sun J, Hu Z, Xiang H, Knight JC, Dong T, Jin R. Interferon-induced transmembrane protein-3 genetic variant rs12252-C is associated with disease severity in COVID-19. *J Infect Dis* 2020;222:34-7.
[PUBMED](#) | [CROSSREF](#)
58. Poddar S, Hyde JL, Gorman MJ, Farzan M, Diamond MS. The interferon-stimulated gene IFITM3 restricts infection and pathogenesis of arthritogenic and encephalitic alphaviruses. *J Virol* 2016;90:8780-94.
[PUBMED](#) | [CROSSREF](#)
59. Yáñez DC, Sahni H, Ross S, Solanki A, Lau CI, Papaioannou E, Barbarulo A, Powell R, Lange UC, Adams DJ, Barenco M, Ono M, D'Acquisto F, Furmanski AL, Crompton T. IFITM proteins drive type 2 T helper cell differentiation and exacerbate allergic airway inflammation. *Eur J Immunol* 2019;49:66-78.
[PUBMED](#) | [CROSSREF](#)
60. Lindsley AW, Schwartz JT, Rothenberg ME. Eosinophil responses during COVID-19 infections and coronavirus vaccination. *J Allergy Clin Immunol* 2020;146:1-7.
[PUBMED](#) | [CROSSREF](#)
61. Chen WH, Strych U, Hotez PJ, Bottazzi ME. The SARS-CoV-2 vaccine pipeline: an overview. *Curr Trop Med Rep* 2020:1-4.
[PUBMED](#)
62. Groot Kormelink T, Pardo A, Knipping K, Buendía-Roldán I, García-de-Alba C, Blokhuis BR, Selman M, Redegeld FA. Immunoglobulin free light chains are increased in hypersensitivity pneumonitis and idiopathic pulmonary fibrosis. *PLoS One* 2011;6:e25392.
[PUBMED](#) | [CROSSREF](#)
63. Wang D, Hu B, Hu C, Zhu F, Liu X, Zhang J, Wang B, Xiang H, Cheng Z, Xiong Y, Zhao Y, Li Y, Wang X, Peng Z. Clinical characteristics of 138 hospitalized patients with 2019 novel coronavirus-infected pneumonia in Wuhan, China. *JAMA* 2020;323:1061-9.
[PUBMED](#) | [CROSSREF](#)
64. Lima MS, Coletta EN, Ferreira RG, Jasinowodolinski D, Arakaki JS, Rodrigues SC, Rocha NA, Pereira CA. Subacute and chronic hypersensitivity pneumonitis: histopathological patterns and survival. *Respir Med* 2009;103:508-15.
[PUBMED](#) | [CROSSREF](#)
65. Günther A, Ruppert C, Schmidt R, Markart P, Grimminger F, Walrath D, Seeger W. Surfactant alteration and replacement in acute respiratory distress syndrome. *Respir Res* 2001;2:353-64.
[PUBMED](#) | [CROSSREF](#)
66. Takemura T, Akashi T, Kamiya H, Ikushima S, Ando T, Oritsu M, Sawahata M, Ogura T. Pathological differentiation of chronic hypersensitivity pneumonitis from idiopathic pulmonary fibrosis/usual interstitial pneumonia. *Histopathology* 2012;61:1026-35.
[PUBMED](#) | [CROSSREF](#)
67. Wang J, Wang BJ, Yang JC, Wang MY, Chen C, Luo GX, He WF. Advances in the research of mechanism of pulmonary fibrosis induced by corona virus disease 2019 and the corresponding therapeutic measures. *Zhonghua Shao Shang Za Zhi* 2020;36:E006.
[PUBMED](#)
68. Bernheim A, Mei X, Huang M, Yang Y, Fayad ZA, Zhang N, Diao K, Lin B, Zhu X, Li K, Li S, Shan H, Jacobi A, Chung M. Chest CT findings in coronavirus disease-19 (COVID-19): relationship to duration of infection. *Radiology* 2020:200463.
[PUBMED](#) | [CROSSREF](#)
69. Lal A, Akhtar J, Pinto S, Grewal H, Martin K. Recurrent pulmonary embolism and hypersensitivity pneumonitis secondary to aspergillus, in a compost plant worker: case report and review of literature. *Lung* 2018;196:553-60.
[PUBMED](#) | [CROSSREF](#)
70. Faverio P, De Giacomi F, Sardella L, Fiorentino G, Carone M, Salerno F, Ora J, Rogliani P, Pellegrino G, Sferrazza Papa GF, Bini F, Bodini BD, Messinesi G, Pesci A, Esquinas A. Management of acute respiratory failure in interstitial lung diseases: overview and clinical insights. *BMC Pulm Med* 2018;18:70.
[PUBMED](#) | [CROSSREF](#)